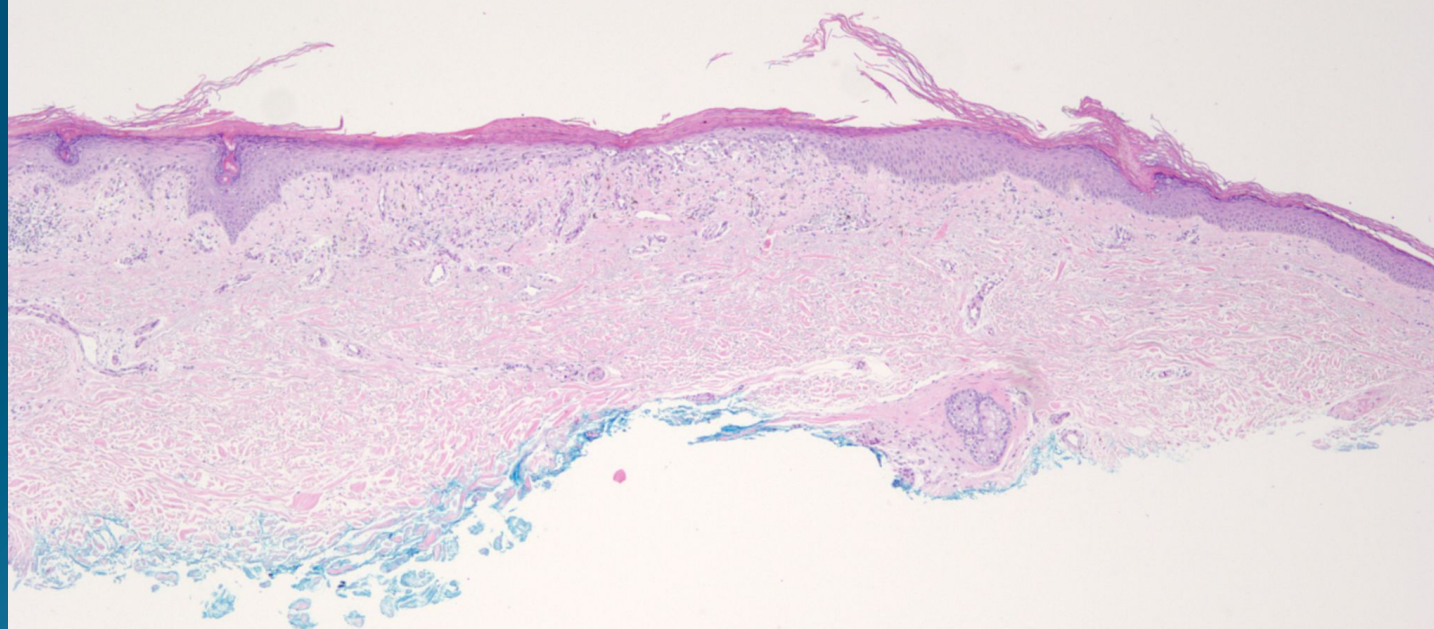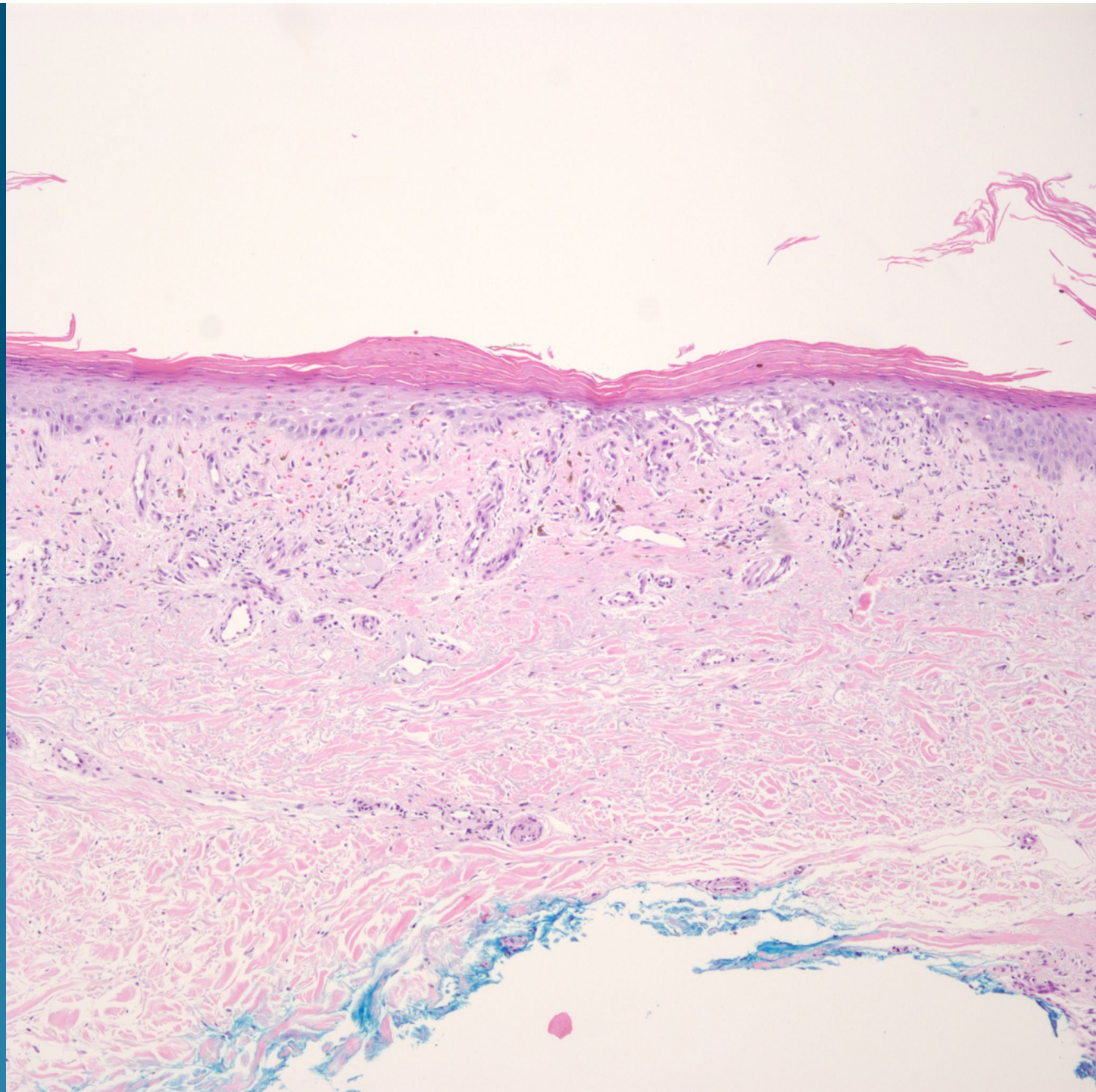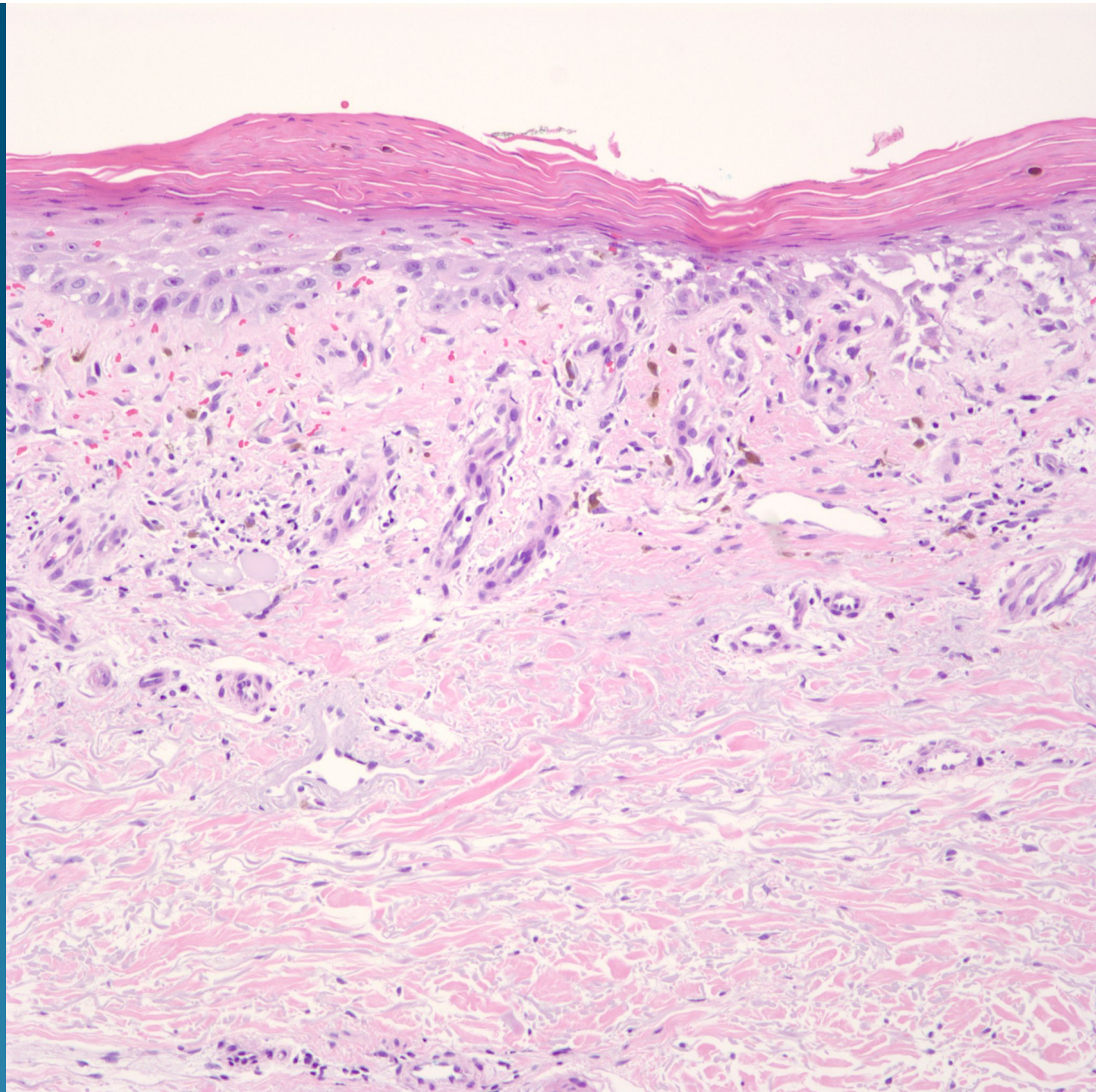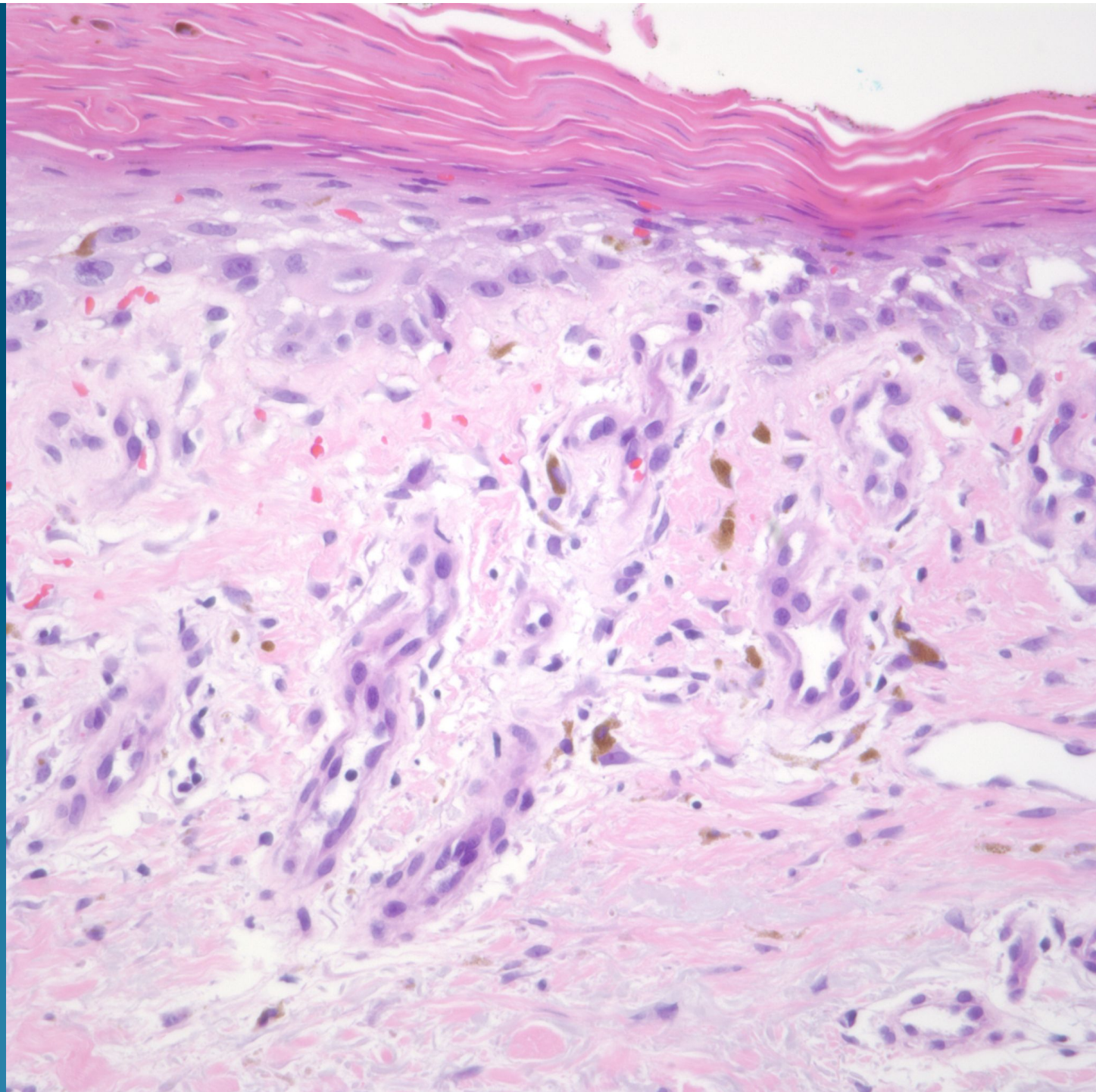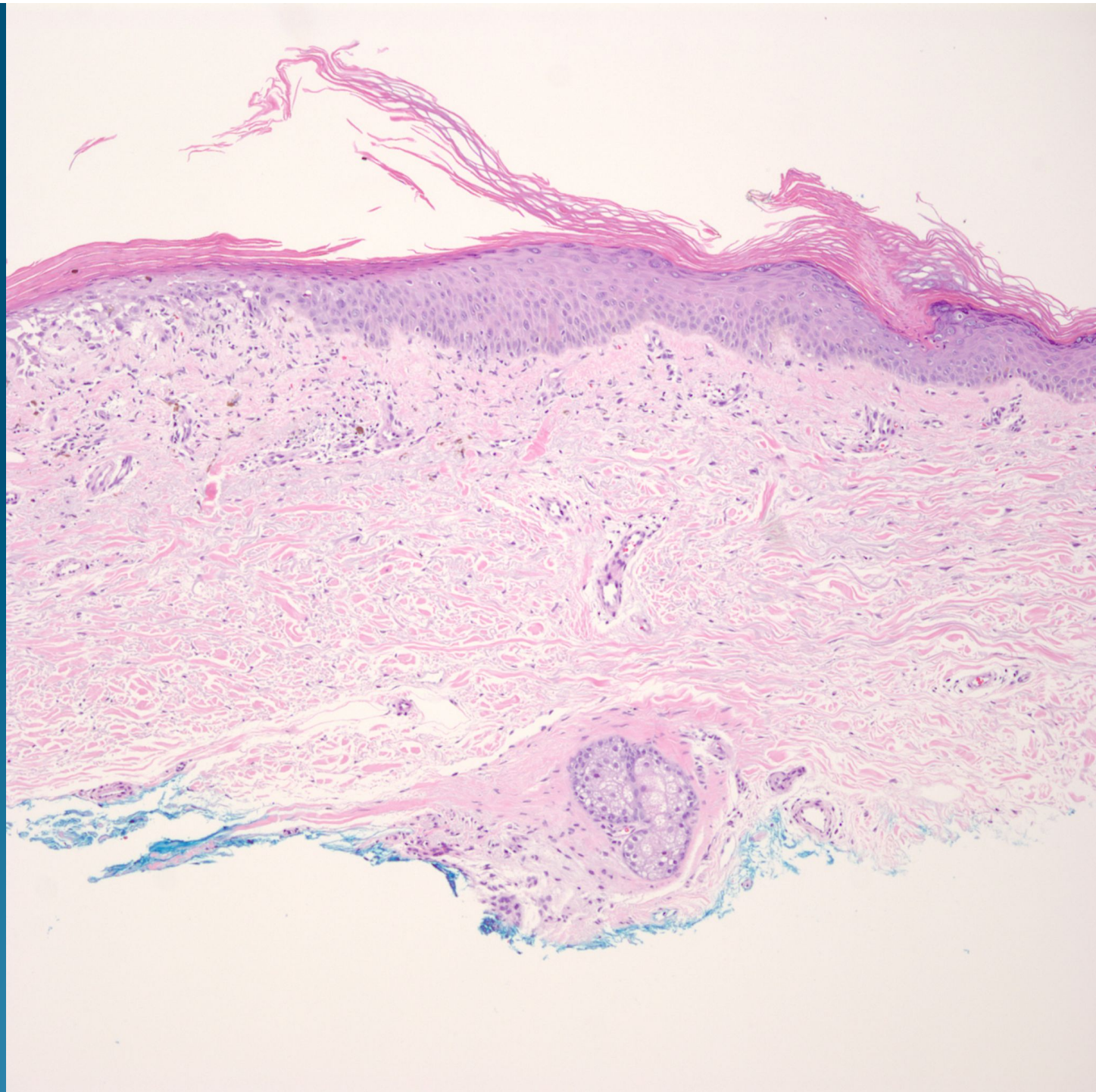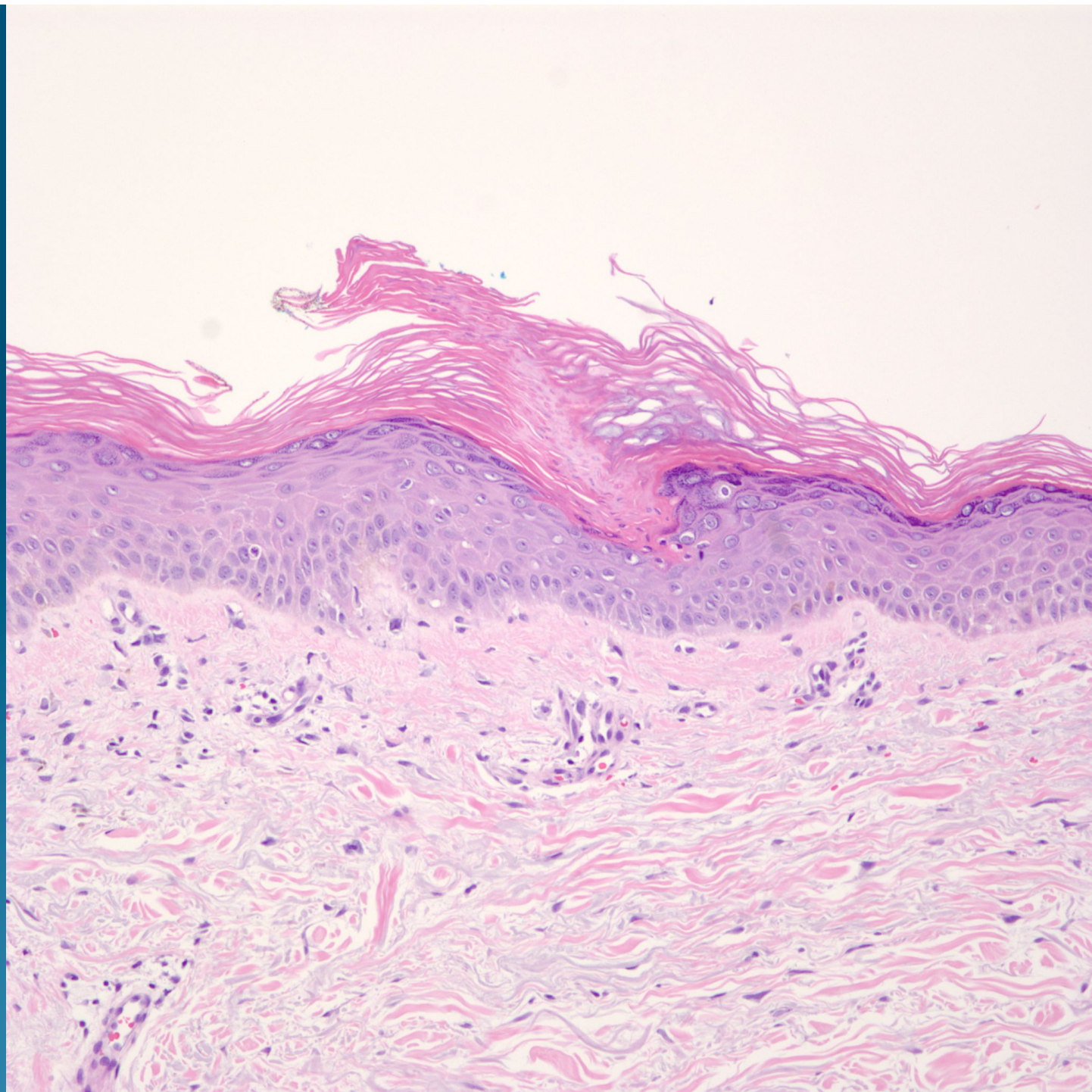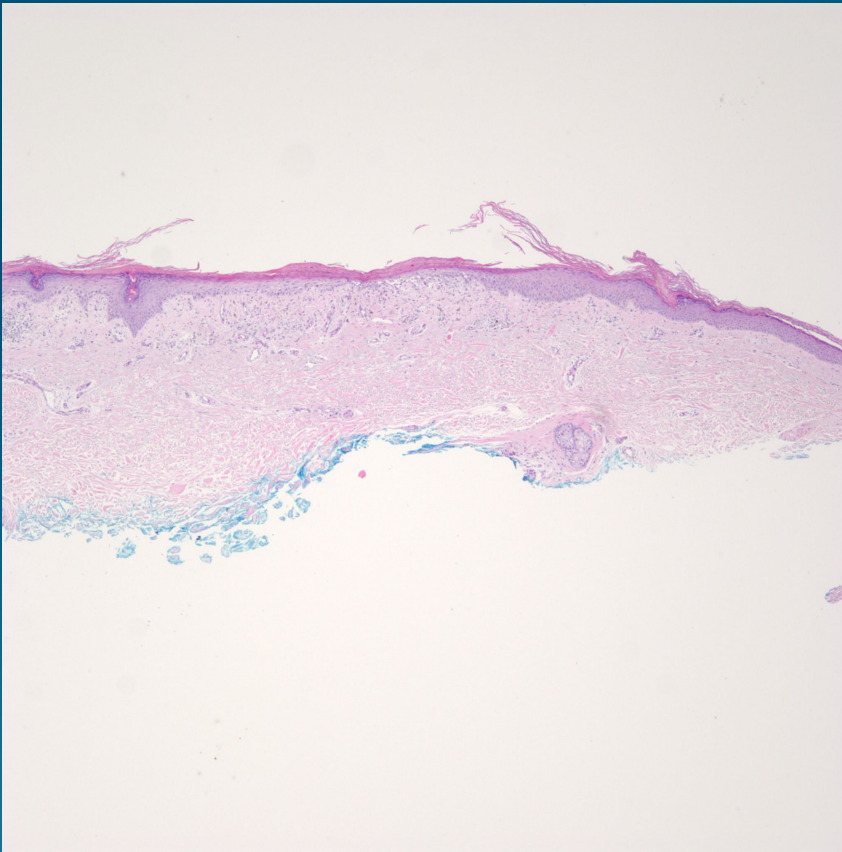


What is the best diagnosis?

- A. Porokeratosis (DSAP type)
- B. Porokeratosis (Mibelli type)
- C. Atrophic actinic keratosis
- D. Atrophic lichen planus
- E. Lichen sclerosis

Porokeratosis (Disseminated Superficial Actinic Porokeratosis)

Pearls



- Look for characteristic cornoid lamella
- Center of lesion may show epidermal atrophy and a lichenoid dermatitis, always cut deepers to see entire lesion